

"US na Classificação dos Tumores Ovarianos"

Prof. Dr. Ayrton R. Pastore

3

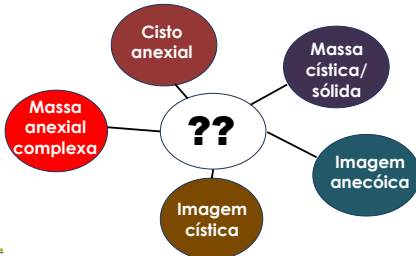US na Classificação dos Tumores Ovarianos

Sumário

- Léxico IOTA/O-RADS US (ACR)
- Classificação e modelos IOTA
- Classificação e Estratificação de Risco O-RADS US (ACR)

4

Massas ovarianas: como descrever ?



5

Classificação dos Tumores Ovarianos pela IOTA

Relatórios com descrição
e padronização uniformes

Timmerman D e cols. Ultrasound Obstet Gynecol 2000; 16: 500-505 IOTA – International Ovarian Tumor Analysis

6

Classificação dos Tumores Ovarianos pela IOTA

Morfologia US	n1233	maligno	%
Unilocular	384	5	0,8
Unilocular c/ comp. sólido	143	44	37
Multilocular	213	20	10
Multilocular c/ comp. Sólido	323	116	43
Sólido	170	84	65

Timmerman D et al. Ultrasound Obstet. Gynecol 2008; 33: 583-90 IOTA – International Ovarian Tumor Analysis



7

Ovarian-Adnexal Reporting Lexicon for Ultrasound: A White Paper of the ACR Ovarian-Adnexal Reporting and Data System Committee



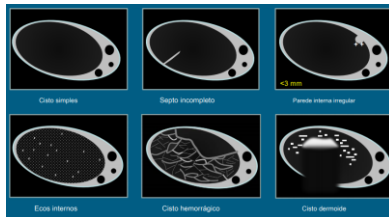
Rachelle F. Andreati, MD¹, Dirk Timmerman, MD, PhD^{2,3}, Beryl R. Benacerraf, MD⁴,
Genevieve L. Benmont, MD⁵, Tom Bruneau, PhD⁶, Douglas L. Brown, MD⁷, Beverly G. Coleman, MD⁸,
Mary C. Frates, MD⁹, Winter Freeman, MD¹⁰, Steven R. Goldstein, MD¹¹,
Ulrike M. Hampel, MD, MBA¹², Mandy M. Harlow, MD¹³, Maria Hernando-Schulman, MD¹⁴,
Caroline Reinhold, MD, MSc¹⁵, Lori M. Strachowski, MD¹⁶, Phyllis Glonek, MD¹⁷

J Am Coll Radiol 2018;15:1415-1429. Copyright © 2018 American College of Radiology



8

Léxico O-RADS US - Cisto unilocular sem componente sólido

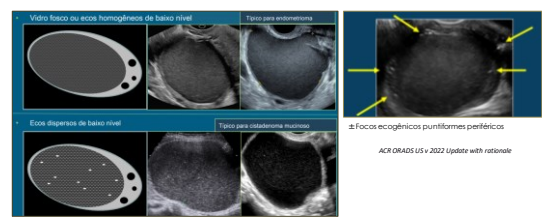


Andreati RF et cols. J Am Coll Radiol 2018; 15: 1415-1429. Ovarian-Adnexal Reporting Lexicon for Ultrasound: A white paper of the ACR Ovarian-Adnexal Reporting and Data System Committee



9

Léxico O-RADS US – Conteúdo do cisto

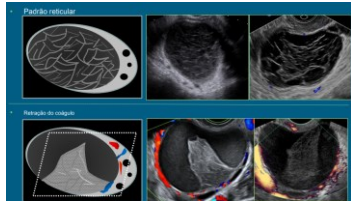


Andreati RF et cols. J Am Coll Radiol 2018; 15: 1415-1429. Ovarian-Adnexal Reporting Lexicon for Ultrasound: A white paper of the ACR Ovarian-Adnexal Reporting and Data System Committee



10

Léxico O-RADS US – Descritores para cisto hemorrágico



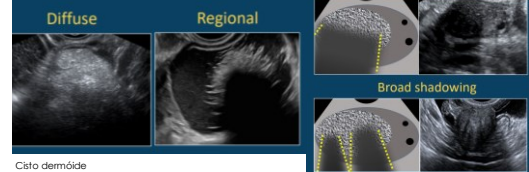
Andreotti RF e cols. J Am Coll Radiol 2018; 15: 1415-1429. Ovarian Adnexal Reporting Lexicon for Ultrasound: A white paper of the ACR Ovarian Adnexal Reporting and Data System Committee



11

Léxico O-RADS US – Sombra

Lesões ovarianas benignas clássicas



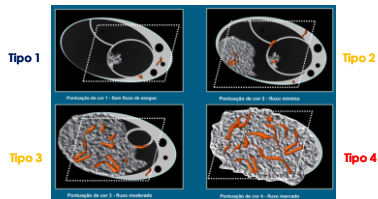
Cisto dermóide

ACR O-RADS US v 2022 Update with rationale



12

Léxico O-RADS US – Escore do Mapa vascular pelo Doppler colorido

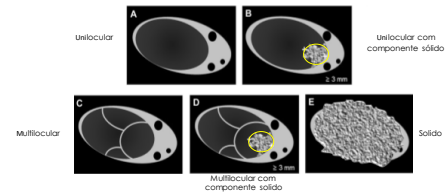


Andreotti RF e cols. J Am Coll Radiol 2018; 15: 1415-1429. Ovarian Adnexal Reporting Lexicon for Ultrasound: A white paper of the ACR Ovarian Adnexal Reporting and Data System Committee



13

Classificação dos Tumores Ovarianos pelo O-RADS US




Andreotti RF e cols. J Am Coll Radiol 2018; 15: 1415-1429. Ovarian Adnexal Reporting Lexicon for Ultrasound: A white paper of the ACR Ovarian Adnexal Reporting and Data System Committee



14

Classificação dos Tumores Ovarianos pelo O-RADS US



Bilocular 2 lojas - septo único

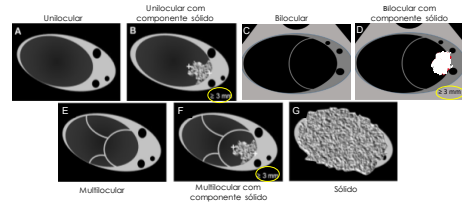
Multilocular ≥ 3 lojas

ACR O-RADS US v 2022 Update with rationale



15

Classificação dos Tumores Ovarianos pelo O-RADS US



Multilocular

Multilocular com componente sólido

Sólido

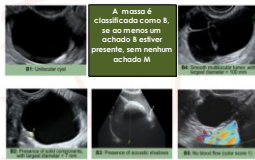ACR O-RADS US v 2022 Update with rationale



16

Regras Simples da IOTA

5 regras simples para prever benignidade



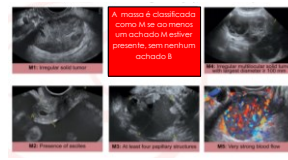
Timmerman et al. Ultrasound Obstet. Gynecol 2008; 31: 681-90 IOTA – International Ovarian Tumor Analysis



18

Regras Simples da IOTA


5 regras simples para prever malignidade



Timmerman et al. Ultrasound Obstet. Gynecol 2008; 31: 681-90 IOTA – International Ovarian Tumor Analysis



19



ADENEX
Assessment of Different
Metastases in the adrenal

The ADENEX model evaluates the risk that a detected adrenal mass is malignant based on indicators such as: demographics, imaging, laboratory, stage I-V, invasive or metastatic cancer to the adrenal.

Start Analysis!

ADNEX IOTA


Tritos preditores não Us


- Idade do paciente
- CA 125 U/mL sérico
- Hospital (oncológico ou não)

Sais preditores ultrasonográficos

- Diâmetro máximo da lesão (mm)
- Proporção (R) do tecido sólido
- Nº de papilas (0,1,2,3,≥4)
- Presença de > 10 lóculos (sim/não)
- Sombras acústicas (sim/não)
- Presença de ascite (sim/não)

Van Gabbler et al, BMC, 2014; 349: 15020





20

ADNEX IOTA

Olinetromidom do lado
 H5 (PCL x 100; 5 fadozido)
 H5 (PCL x 100; 5 fadozido)
 H5 (PCL x 100; 5 fadozido)
 H5 (PCL x 100; 5 fadozido)
 H5 (PCL x 100; 5 fadozido)
 H5 (PCL x 100; 5 fadozido)

N° de papila: 2,3,24
 Sombra acústica (3 ou 4)
 Sombra acústica (3 ou 4)
 Sombra acústica (3 ou 4)
 Sombra acústica (3 ou 4)
 Sombra acústica (3 ou 4)
 Sombra acústica (3 ou 4)

Von Callier et al. BMJ. 2014; 349: 5502

Ginecologia
 1100
 1100

21

ADNEX IOTA

Column

READ OF THE RESULTS

Sensitivity

Specificity

Baseline

Patient

Radar

A

B

C

D

E

Green points: Baseline

Red points: Patient

Van Calster et al, BMJ. 2014; 349: 5920

ADNEX IOTA

23

O-RADS US Risk Stratification and Management System:
A Consensus Guideline from the ACR Ovarian-Adnexal
Reporting and Data System Committee

*Richard E. Anderson, MD¹ • Dahl Tosteson, MD PhD² • Lori M. Spachowitz, MD³ • Waseem Fattom, MD⁴ •
Beryl S. Hwang, MD⁵ • Jennifer L. Boman, MD⁶ • John M. Gattuso, MD⁷ • Douglas B. Kirsch, MD⁸ •
Randy G. Coleman, MD⁹ • Mary C. Frum, MD¹⁰ • Steven R. Goldstein, MD¹¹ • Linda M. Hwang, MD, MBA¹² •
Mark M. Hirsch, MD¹³ • Maria Tsimpanogiannis, MD PhD¹⁴ • Caroline Winkler, MD¹⁵ • Stephen L. Rose, MD¹⁶ •
David P. Witwitsky, MD¹⁷ • Wendy L. Wolfson, MD¹⁸ • Phyllis Glack, MD¹⁹*

From the ¹University of Michigan, Ann Arbor, MI; ²University of Minnesota, Minneapolis, MN; ³University of California, Los Angeles, CA; ⁴University of Illinois at Chicago, Chicago, IL; ⁵University of Wisconsin, Madison, WI; ⁶University of Texas at Dallas, Dallas, TX; ⁷University of Michigan, Ann Arbor, MI; ⁸University of Michigan, Ann Arbor, MI; ⁹University of Michigan, Ann Arbor, MI; ¹⁰University of Michigan, Ann Arbor, MI; ¹¹University of Michigan, Ann Arbor, MI; ¹²University of Michigan, Ann Arbor, MI; ¹³University of Michigan, Ann Arbor, MI; ¹⁴University of Michigan, Ann Arbor, MI; ¹⁵University of Michigan, Ann Arbor, MI; ¹⁶University of Michigan, Ann Arbor, MI; ¹⁷University of Michigan, Ann Arbor, MI; ¹⁸University of Michigan, Ann Arbor, MI; ¹⁹University of Michigan, Ann Arbor, MI.

Received October 1, 2019; accepted November 1, 2019. Address correspondence to: Richard E. Anderson, MD, Department of Radiology, University of Michigan, 1500 University Ave, Ann Arbor, MI 48106-0710; e-mail: andersonr@umich.edu.

© 2020 American College of Radiology. All rights reserved. This article is intended solely for the personal use of the individual user and is not to be disseminated broadly.

DOI: 10.1016/j.acr.2020.09.001

Published online 10 October 2020

Supplemental material is available for this article. URL: <https://doi.org/10.1016/j.acr.2020.09.001>.

Address reprint requests to: Richard E. Anderson, MD, Department of Radiology, University of Michigan, 1500 University Ave, Ann Arbor, MI 48106-0710; e-mail: andersonr@umich.edu.

© 2020 American College of Radiology. All rights reserved. This article is intended solely for the personal use of the individual user and is not to be disseminated broadly.

DOI: 10.1016/j.acr.2020.09.001

Published online 10 October 2020

Supplemental material is available for this article. URL: <https://doi.org/10.1016/j.acr.2020.09.001>.

Address reprint requests to: Richard E. Anderson, MD, Department of Radiology, University of Michigan, 1500 University Ave, Ann Arbor, MI 48106-0710; e-mail: andersonr@umich.edu.

© 2020 American College of Radiology. All rights reserved. This article is intended solely for the personal use of the individual user and is not to be disseminated broadly.

DOI: 10.1016/j.acr.2020.09.001

Published online 10 October 2020

Supplemental material is available for this article. URL: <https://doi.org/10.1016/j.acr.2020.09.001>.

Address reprint requests to: Richard E. Anderson, MD, Department of Radiology, University of Michigan, 1500 University Ave, Ann Arbor, MI 48106-0710; e-mail: andersonr@umich.edu.

© 2020 American College of Radiology. All rights reserved. This article is intended solely for the personal use of the individual user and is not to be disseminated broadly.

DOI: 10.1016/j.acr.2020.09.001

Published online 10 October 2020

Supplemental material is available for this article. URL: <https://doi.org/10.1016/j.acr.2020.09.001>.

Address reprint requests to: Richard E. Anderson, MD, Department of Radiology, University of Michigan, 1500 University Ave, Ann Arbor, MI 48106-0710; e-mail: andersonr@umich.edu.

© 2020 American College of Radiology. All rights reserved. This article is intended solely for the personal use of the individual user and is not to be disseminated broadly.

DOI: 10.1016/j.acr.2020.09.001

Published online 10 October 2020

Supplemental material is available for this article. URL: <https://doi.org/10.1016/j.acr.2020.09.001>.

Address reprint requests to: Richard E. Anderson, MD, Department of Radiology, University of Michigan, 1500 University Ave, Ann Arbor, MI 48106-0710; e-mail: andersonr@umich.edu.

© 2020 American College of Radiology. All rights reserved. This article is intended solely for the personal use of the individual user and is not to be disseminated broadly.

DOI: 10.1016/j.acr.2020.09.001

Published online 10 October 2020

Supplemental material is available for this article. URL: <https://doi.org/10.1016/j.acr.2020.09.001>.

Address reprint requests to: Richard E. Anderson, MD, Department of Radiology, University of Michigan, 1500 University Ave, Ann Arbor, MI 48106-0710; e-mail: andersonr@umich.edu.

© 2020 American College of Radiology. All rights reserved. This article is intended solely for the personal use of the individual user and is not to be disseminated broadly.

DOI: 10.1016/j.acr.2020.09.001

Published online 10 October 2020

Supplemental material is available for this article. URL: <https://doi.org/10.1016/j.acr.2020.09.001>.

Address reprint requests to: Richard E. Anderson, MD, Department of Radiology, University of Michigan, 1500 University Ave, Ann Arbor, MI 48106-0710; e-mail: andersonr@umich.edu.

© 2020 American College of Radiology. All rights reserved. This article is intended solely for the personal use of the individual user and is not to be disseminated broadly.

DOI: 10.1016/j.acr.2020.09.001

Published online 10 October 2020

Supplemental material is available for this article. URL: <https://doi.org/10.1016/j.acr.2020.09.001>.

Address reprint requests to: Richard E. Anderson, MD, Department of Radiology, University of Michigan, 1500 University Ave, Ann Arbor, MI 48106-0710; e-mail: andersonr@umich.edu.

© 2020 American College of Radiology. All rights reserved. This article is intended solely for the personal use of the individual user and is not to be disseminated broadly.

DOI: 10.1016/j.acr.2020.09.001

Published online 10 October 2020

Supplemental material is available for this article. URL: <https://doi.org/10.1016/j.acr.2020.09.001>.

Address reprint requests to: Richard E. Anderson, MD, Department of Radiology, University of Michigan, 1500 University Ave, Ann Arbor, MI 48106-0710; e-mail: andersonr@umich.edu.

© 2020 American College of Radiology. All rights reserved. This article is intended solely for the personal use of the individual user and is not to be disseminated broadly.

DOI: 10.1016/j.acr.2020.09.001

Published online 10 October 2020

Supplemental material is available for this article. URL: <https://doi.org/10.1016/j.acr.2020.09.001>.

Address reprint requests to: Richard E. Anderson, MD, Department of Radiology, University of Michigan, 1500 University Ave, Ann Arbor, MI 48106-0710; e-mail: andersonr@umich.edu.

© 2020 American College of Radiology. All rights reserved. This article is intended solely for the personal use of the individual user and is not to be disseminated broadly.

DOI: 10.1016/j.acr.2020.09.001

Published online 10 October 2020

Supplemental material is available for this article. URL: <https://doi.org/10.1016/j.acr.2020.09.001>.

Address reprint requests to: Richard E. Anderson, MD, Department of Radiology, University of Michigan, 1500 University Ave, Ann Arbor, MI 48106-0710; e-mail: andersonr@umich.edu.

© 2020 American College of Radiology. All rights reserved. This article is intended solely for the personal use of the individual user and is not to be disseminated broadly.

DOI: 10.1016/j.acr.2020.09.001

Published online 10 October 2020

Supplemental material is available for this article. URL: <https://doi.org/10.1016/j.acr.2020.09.001>.

Address reprint requests to: Richard E. Anderson, MD, Department of Radiology, University of Michigan, 1500 University Ave, Ann Arbor, MI 48106-0710; e-mail: andersonr@umich.edu.

© 2020 American College of Radiology. All rights reserved. This article is intended solely for the personal use of the individual user and is not to be disseminated broadly.

DOI: 10.1016/j.acr.2020.09.001

Published online 10 October 2020

Supplemental material is available for this article. URL: <https://doi.org/10.1016/j.acr.2020.09.001>.

Address reprint requests to: Richard E. Anderson, MD, Department of Radiology, University of Michigan, 1500 University Ave, Ann Arbor, MI 48106-0710; e-mail: andersonr@umich.edu.

© 2020 American College of Radiology. All rights reserved. This article is intended solely for the personal use of the individual user and is not to be disseminated broadly.

DOI: 10.1016/j.acr.2020.09.001

Published online 10 October 2020

Supplemental material is available for this article. URL:

24

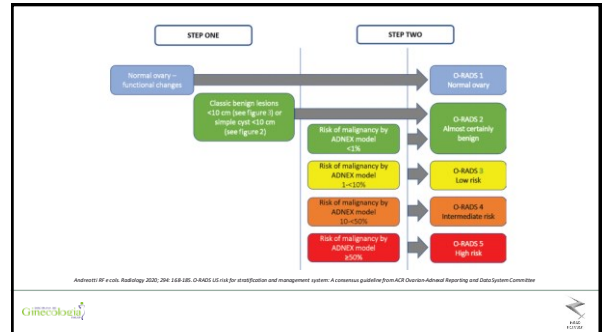
Classificação de risco dos tumores ovarianos pelo O-RADS US

- 0 – Avaliação incompleta
- 1 – Normal – Fisiológica
- 2 – Muito provavelmente benigno (risco < 1% para malignidade)
- 3 – Risco baixo (1 a <10% para malignidade)
- 4 – Risco moderado (10 a < 50% para malignidade)
- 5 – Risco elevado (≥ 50% para malignidade)

Andreotti RF et al. Radiology 2020; 294: 169-185. O-RADS US risk for stratification and management system: A consensus guideline from ACR Ovarian-Adnexal Reporting and Data System Committee



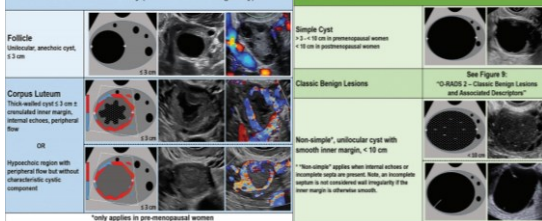
25



26

Classificação de risco dos tumores ovarianos pelo O-RADS US

O-RADS 1 – Normal Ovary (0% likelihood of malignancy)*

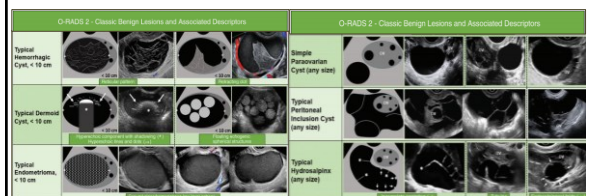


Andreotti RF et al. Radiology 2020; 294: 169-185. O-RADS US risk for stratification and management system: A consensus guideline from ACR Ovarian-Adnexal Reporting and Data System Committee



27

Classificação de risco dos tumores ovarianos pelo O-RADS US



Andreotti RF et al. Radiology 2020; 294: 169-185. O-RADS US risk for stratification and management system: A consensus guideline from ACR Ovarian-Adnexal Reporting and Data System Committee



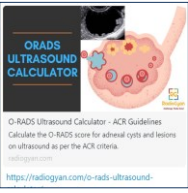
28

Lexicon Terminology and Definitions – Updates Bilocular			
Version 2019		Version 2022	
Category	Definition	Category	Definition
1. Benign	Benign lesions are those that are not malignant and do not have the potential to become malignant.	1. Benign	Benign lesions are those that are not malignant and do not have the potential to become malignant.
2. Indeterminate	Indeterminate lesions are those that are not clearly benign or malignant and require further evaluation.	2. Indeterminate	Indeterminate lesions are those that are not clearly benign or malignant and require further evaluation.
3. Malignant	Malignant lesions are those that are clearly malignant and have the potential to spread to other parts of the body.	3. Malignant	Malignant lesions are those that are clearly malignant and have the potential to spread to other parts of the body.

ACR O-RADS US v 2022 Update with rationale

32

Classificação de risco dos tumores ovarianos pelo O-RADS US



O-RADS Ultrasound Calculator - ACR Guidelines
Calculate the O-RADS score for adnexal cysts and lesions on ultrasound as per the ACR criteria.
<https://radiogain.com/o-rads-ultrasound/>

Ovarian lesions

Normal Ovary

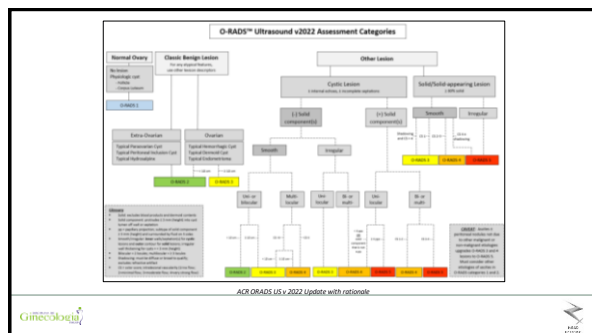
Classic

Non-classic

Incomplete evaluation

ACR O-RADS US v 2022 Update with rationale

33



34

O-RADS US

Considerações finais

- 1ª " " aplicar o Léxico e a Classificação O-RADS US"
- 2ª Estratificação de risco "O-RADS US"
- O modelo O-RADS facilita a comunicação com o médico e o paciente
- A avaliação subjetiva da US pelo expert parece ser o melhor método para prever malignidade (IOTA)

ACR O-RADS US v 2022 Update with rationale

35